Real world outcomes of delayed cytoreductive nephrectomy in metastatic Renal cell carcinoma following systemic therapy :A tertiary center experience

M. Hassan , H. Warren , R. Nair , D. Crawley , A. Khan , A. Fernando , T. O Brian , S. Rudman
Guys and St Thomas hospital

Background:

The role of cytoreductive nephrectomy in metastatic renal cell carcinoma patients has been an area of interest since the era of Interferon, cytokine therapy and the tyrosine kinase inhibitor therapy. Now that immune checkpoint inhibitors producing long term durable responses are established in the treatment of mRCC patients, it is important to evaluate real world data to understand which patients are proceeding to cytoreductive nephrectomy and if they are benefiting from this.

Here we report real-world pathological and clinical outcomes of delayed CN following first-line systemic therapy at a tertiary referral center.

Characteristic	Value
Patients (N)	11
Median age	64 years
Sex	8 male · 3 female
ECOG performance status	0–1 (all patients)
Histology	Clear cell, 10 · NOS, 1
Metastatic sites	Lung only, 8 · LN only, 1 Lung+adrenal, 1 · Lung+pancreas, 1
First-line therapy	IPI/NIVO, 9 · Pazopanib, 1 Cabozantinib, 1
Surgical approach	Robotic-assisted, 7 · Open, 4
Median time to surgery	22 months

Fig 1 Patient baseline characteristics

Complete Pathological Response

45%

5 of 11 patients achieved a complete pathological response — all had received first-line IPI/NIVO

Pathological Response by First-Line Regimen

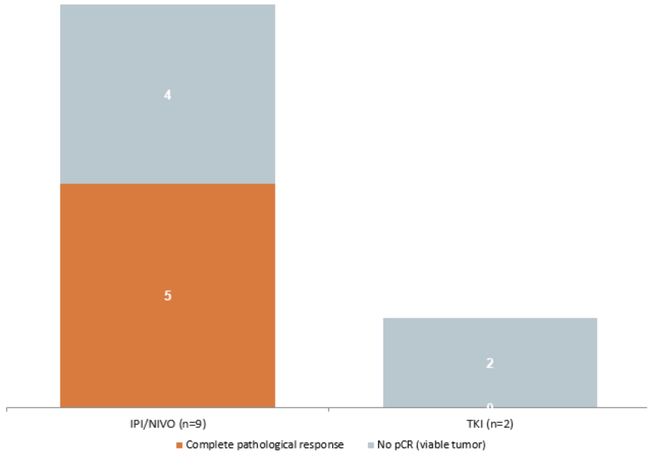

Methods:

We conducted a retrospective analysis of all mRCC patients who underwent delayed CN after first-line systemic therapy (tyrosine kinase inhibitors [TKI] or ipilimumab/nivolumab [IPI/NIVO]) between 2019- 2023 .
Baseline characteristics, treatment details, and surgical outcomes were collected.

Follow up :

- 4 of 5 pCR patients remained progression-free at last follow-up; 1 progressed and was switched to second-line cabozantinib.
- Both TKI-treated patients had viable tumor at surgery and subsequently progressed to second-line therapy.
- 10 of 11 patients remain alive; 1 died of a non-cancer-related cause with no evidence of disease recurrence.

Conclusion :

Deferred cytoreductive nephrectomy remains a possible valuable treatment strategy for selected patients with metastatic RCC in the modern SACT era. Notably, a significant minority achieve complete response, with some maintaining durable treatment-free intervals on follow up